

Computer-Assisted Surgery: Pros and Cons

James B. Stiehl¹

St Mary's/Good Samaritan Hospital, 1054 Martin Luther King Drive, #226, Centralia, IL, USA

James B. Stiehl

Email: jbstiehl@me.com

[Introduction](#)

[Pros](#)

[Cons](#)

[Conclusion](#)

[References](#)

Abstract

Computer navigation is an important method in orthopedic surgery improving the accuracy and precision of surgical interventions. The basic technology of digital imaging with digital cameras has improved to submicron accuracy. The ability to make the surgical targets virtual on a monitor has evolved to the point where the capabilities have exceeded the limitations of cost, complexity, and inefficiency. In addition, various parallel technologies such as intraoperative computed tomography will automate the registration process to a few seconds. Patient-specific cutting guides are another example of the example utilizing preoperative imaging to create custom cutting guides. National joint registry data from Australia have show that long-term revision rates are lower in patients who have had navigated total knees. Detractors still identify the precision problems of imageless registration, and pin complications for the bone anchoring of trackers have a small risk of stress fracture. The overall impression is that various digital imaging systems including robotics, intraoperative computed tomography, and other parallel technologies will produce a “better than not” scenario for the practicing surgeon.

Keywords Blood loss – Computer navigation – Cons – Inherent inaccuracy – Pros – Digital imaging

Introduction

Computer navigation has evolved as an important method in orthopedic surgery for improving the accuracy and precision of surgical interventions. With the advent of the NDI digital camera, it has been possible to track dynamic reference bases or DRBs in “real time” on a computer screen. A DRB could be anything from a femur or tibia to an instrument, saw, or drill. With the advances pioneered by Dr. Stephane Lavallee in total knee replacement, the technology quickly took hold, primarily in Germany and other parts of Europe. Over the past 20 years, we have seen a steady growth in the proliferation of computer-assisted surgery, and we are now reaching the point of “better than not,” which happens with all improvements where the newer technology exceeds previous capabilities. That is to suggest that we now have capabilities such as spine pedicle screw placement where the accepted method requires the newer technology. This has allowed for limited surgical approaches and performing operations where previously, large anatomical exposure was necessary for the guidance landmarks. The other exciting evolution over the past few years has been the proliferation of new technologies into the “space” of computer-assisted surgery. The technologies applied in total knee replacement are markedly streamlined with fewer “bells and whistles” and targeted applications. Patient-specific cutting guides are another example of simplicity, where the guide is created in advance by a vendor, utilizing preoperative CT or MRI scan data to model a cutting guide that is created as a custom device that is then applied intraoperative to the specific patient’s geometry [[1](#), [2](#)]. Accelerometer-based guides offer similar accuracy to conventional computer navigation with a restricted menu of measurements [[3](#)]. Time efficiency has dramatically improved, even for the standard navigational systems, and this comes from the ability of the navigational software protocol to perform only those maneuvers that the surgeon is specifically requiring [[4](#)]. This is in great contrast to the early systems that provided a “standard” method of registration, basic surgical technique, and order of the surgical procedure.

Digital imaging has been a part of robotics and computer navigation from the outset and has been characterized by the need of a preoperative CT scan or MRI. Early on with the ROBODOC system, the digital image described the bone dimensions that could be used to create custom prosthetic implants and could guide the milling process of the bone down to submillimeter levels. The MAKO robotic system (Stryker, Inc., Mahwah, NJ) relies on preoperative CT DICOM files that are loaded into the MAKO computer at the time of surgery. Conventional anatomical registration methods are utilized to guide a haptic robot that directs the patient’s bone preparation from a predetermined software protocol. These systems have been shown to have better precision than conventional instrumentation, but require a preoperative CT scan. With the availability of intraoperative 3D/CT such as the Medtronic O-arm, the surgeon will be able to capture the appropriate digital images at the time of surgery, eliminating the preoperative imaging for navigation [[5](#)].

Pros

In total knee replacement, early data on the use of these image-free optical tracking systems appeared positive with improved mechanical alignment, frontal and sagittal femoral axis alignment, and frontal tibial axis alignment. Multiple randomized control trials were able to demonstrate a statistically significant improvement in terms of placing the final mechanical alignment of the knee within 3° of the ideal mechanical axis [[6–20](#)]. We note that 93 % of the overall cases from these studies reach this level of precision with computer navigation compared to 74 % where conventional methods are used (Table [1](#)). Zhang et al. performed a comparison study with bilateral total knees showing that conventional technique resulted in 28 % outside of the 3° mechanical outlier with no cases outlying in the navigation group [[21](#)]. Several meta-analyses have shown the advantage of computer-assisted surgery over conventional techniques for component alignment, blood loss, the Knee Society and WOMAC Scores, and a tendency for fewer overall adverse events [[22–25](#)]. Until recently, outcome data has not been able to demonstrate significant improvements in overall revision rates and general outcomes. However, a review of a large national total knee registry was able to show statistical improvements in the occurrence of implant loosening and osteolysis with the use of computer navigation [[26](#)].

Table 1

Clinical studies that compare the ability of conventional manual surgical techniques with computer navigation for placing the limb alignment within $\pm 3^\circ$ of the mechanical axis of the lower extremity

Author	N	Navigated	Conventional	% Diff.
Haaker et al. [55]	100	96 %	75 %	21 %
Sparmann et al. [56]	120	98 %	78 %	20 %
Victor et al. [57]	50	100 %	74 %	27 %
Jenny et al. [11]	235	97 %	74 %	23 %
Jenny et al. [12]	30,30	83 %	70 %	17 %
Kim et al. [14]	69, 78	78 %	58 %	20 %
Perlick et al. [16]	40	93 %	75 %	28 %
Song et al. [19]	47, 50	96 %	76 %	20 %
Bathis et al. [58]	160	96 %	78 %	18 %
Perlick et al. [16]	50	92 %	72 %	20 %
Hart et al. [9]	60	88 %	70 %	18 %
Anderson et al. [59]	116, 51	95 %	84 %	11 %
		93 % (average)	74 % (<i>P</i> < 0 .001)	20 %

Blood loss has been significantly reduced with the use of computer navigation and avoidance of intramedullary rods [[27](#)– [29](#)]. Kalairajah et al. were able to reduce the mean blood loss from 1747 ccs to 1351 ccs by using the pin-placed trackers instead of intramedullary-guided femur and tibia jigs which was a

significant difference in 60 patients [[30](#)]. McConnell et al. similarly showed the reduction of mean blood loss from 1362 ccs to 1137 ccs with an even larger study including 130 patients [[31](#)]. A number of studies have been able to demonstrate early improvements in functional outcome with computer assisted over conventional [[32](#), [33](#)]. Gothesien et al. showed that the Knee Injury and Osteoarthritis Outcome Score was significantly better for sports and symptoms categories at 1-year follow-up [[34](#)]. Hoffart et al. found that navigation resulted in better mean Knee Society Scores ($p = 0.008$) compared to conventional instruments at 5-year follow-up [[35](#)].

Heyse et al. demonstrated the potential of preoperative digital registration with the creation of patient-specific cutting blocks [[1](#)]. He was able to show that the outliers of greater than 3° from the neutral TEA axis using MRI for femoral component rotation were reduced from 22.9 % with conventional instrumentation and direct resection anatomical references to 2.2 % with patient-specific guides. The ability to assess axial images from preoperative MRI and computed tomography scans clearly exceeds the ability to pick visual landmarks in the intraoperative setting [[36](#), [37](#)]. Tibial rotation alignment of the tibial tray can normally be quite difficult even with navigation of the AP axis of the tibia or other landmarks such as the medial 1/3 of tibial tubercle.

Numerous authors have used CT images to assess these landmarks postoperatively. Roper et al. were able to show interobserver reliability of 0.9 for assessing the position of the medial one-third of the tibial tubercle in relation to the tibial tray postoperative [[38](#)]. Kuriyama et al. have shown tibial tray position can be markedly improved using a CT-based navigation system [[39](#)]. Those authors used the intraoperative registration that was CT based to define the anterior/posterior axis of the tibia and then used a navigation-assisted placement of the tibial tray to demonstrate a precision of $\pm 3^\circ$ for rotational alignment as compared to Akagi's line. An important advantage for using CAS is the ability to carefully measure gap balance through the range of motion [[40–42](#)]. This measurement relies on the inherent precision of measuring the gap distances, and a recent study would suggest that this measure is clearly in the submillimeter range. Walde et al. have used computer navigation to assist the process of femoral rotation determination, noting that the best results were obtained using a tenor ligament balancing method [[43](#)]. They found that using direct measured resection referencing, the resulting femoral rotation varied from 12° of internal rotation to 15° of external rotation. Using tensors with ligament balancing, this was reduced to 3° of internal rotation to 2.5° of external rotation. Hino et al. found significant mid-flexion laxity when measuring the gaps at 10° intervals from 0° to 90° of flexion [[44](#)]. This laxity was not apparent at 0° and 90° and was found to be exaggerated in the posterior-stabilized techniques over the posterior cruciate retaining total knees. A number of studies have shown the ability of CAS to improve outcomes by aiding the surgeon in the ligament release and balancing methods.

Several authors have studied the ability of the computer to capture intraoperative kinematic data, with passive range of motion of the knee before and after prosthesis placement [[45–48](#)]. It is likely that this data could be analyzed with comparison to intraoperative CT data [[37](#)]. This may offer some predictive pre-implant scenarios where the surgeon may optimize various choices of the bone resection steps and even choices of prosthetic geometry. Siston et al. suggested that collecting this type of data could be combined with direct

referencing of femur for improved determination of femoral component rotation. Matziolis et al. used navigation to calculate the flexion axis through the range of motion and with the help of a tensor during the assessment and noted that the measured axis more correctly paralleled the surgical epicondylar axis as compared to direct referenced cuts using the transepicondylar axis or Whiteside's line [[46](#)]. Several authors have been able to demonstrate the ability of computer navigation to guide implant placement in situations where conventional instruments are not applicable. This could include cases of extra-articular deformity and old traumatic cases where prior plates and rods impair the use of intramedullary guides [[5](#), [33](#), [49–53](#)]. I would consider these cases to be of higher complexity, and the surgeon must be fastidious and confident that referencing will be accurate. However, the capability to perform these techniques is obvious and enabling for the experienced surgeon (Fig. [1](#)).

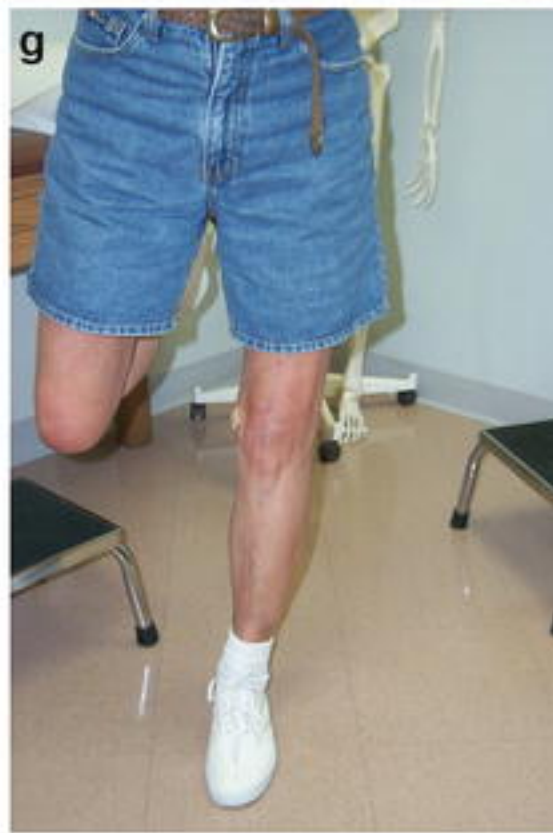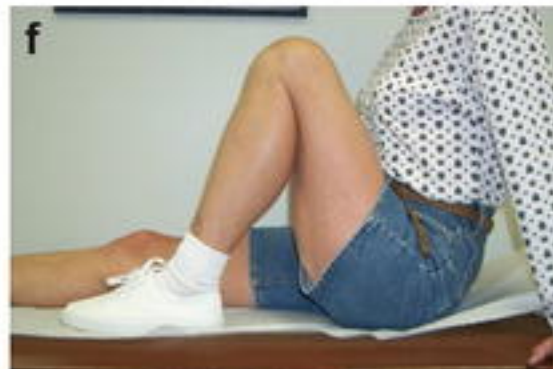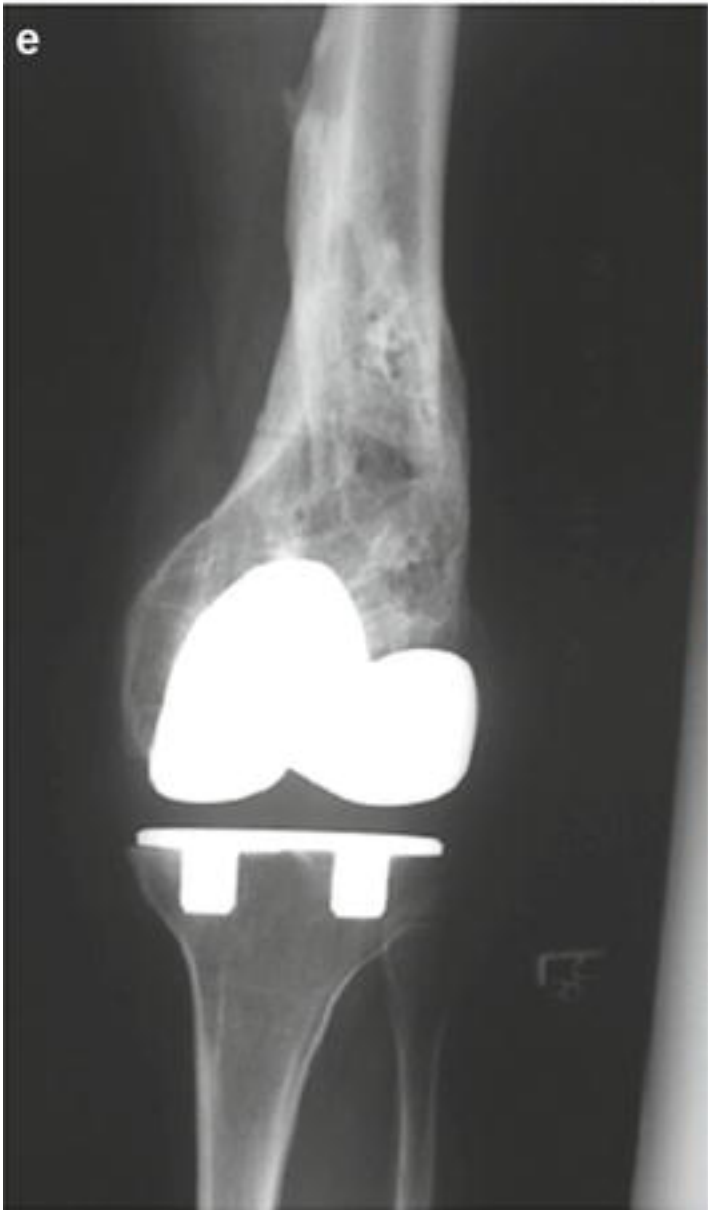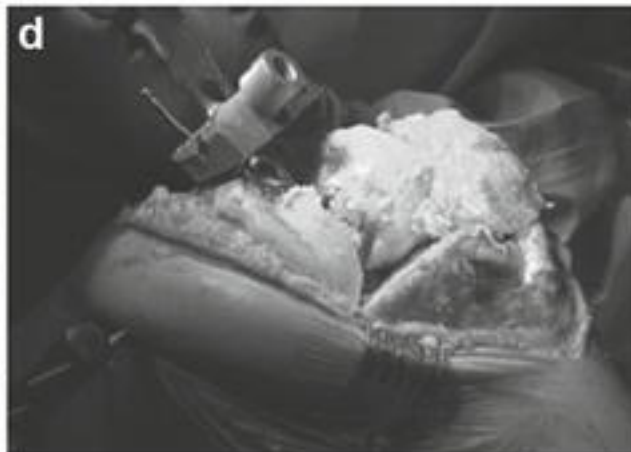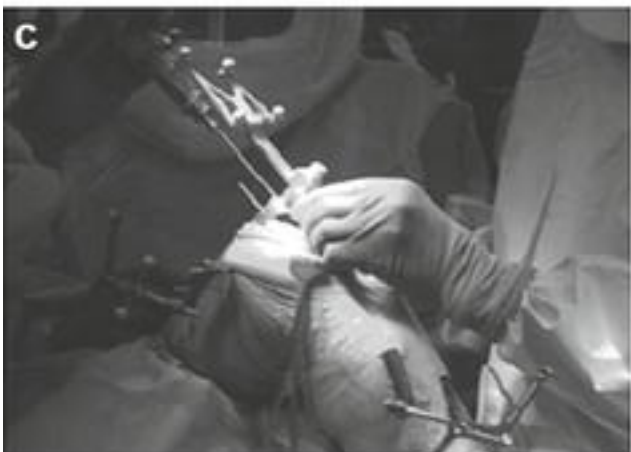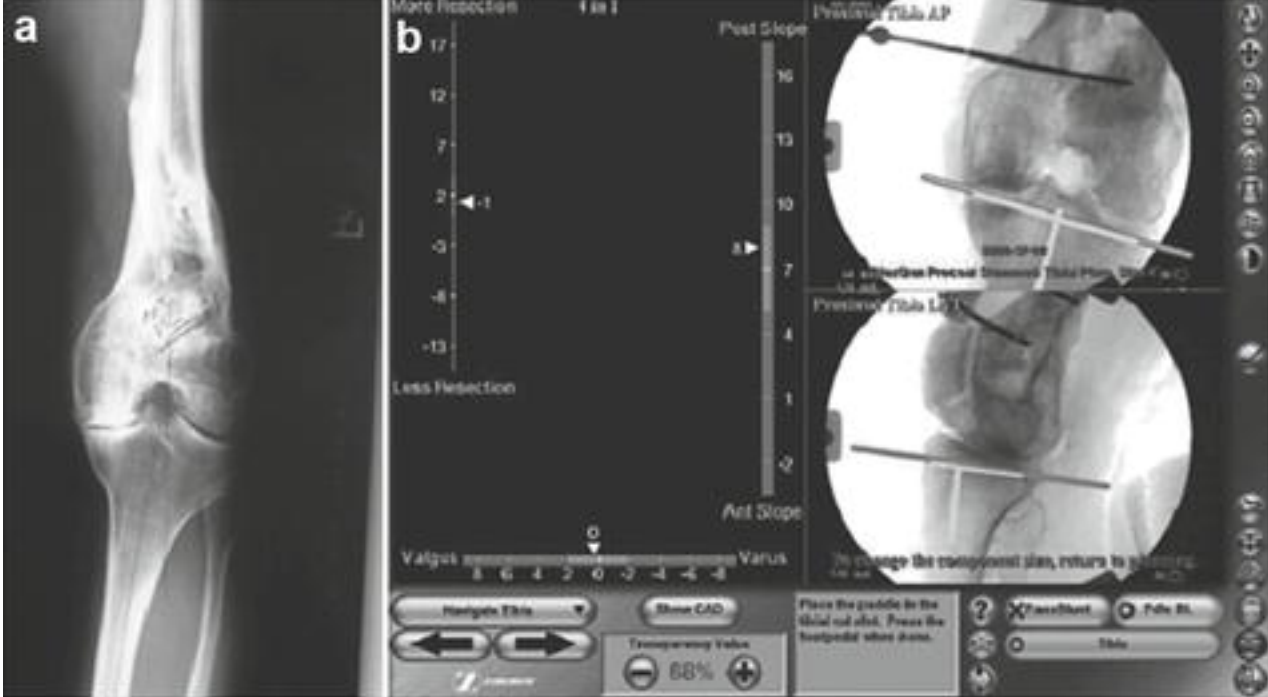


Fig. 1

56-year-old female who over 30 years ago had comminuted left femoral fracture treated with traction resulting in intramedullary canal obstruction and chronic deformity; (**a**) difficult total reconstruction in an old distal femoral fracture deformity. (**b**) Navigation of tibial cut shows planned cut to be 8° posterior slope, 1 mm of medial tibial plateau, and 0° to the mechanical axis. (**c**) Freehand navigation of the distal femoral cutting guide into the desired resection level and correct angle for the coronal and sagittal planes. (**d**) The distal femoral cut is made based on the freehand-navigated position of the cut guide. (**e**) The final radiograph shows the “perfect” position of the distal femoral cut, with a final mechanical axis measurement of 1° varus; (**f**) standing at 1-year post-op; (**g**) amount of postoperative flexion noted at 1 year

A recent publication from the Australian Orthopedic Association National Joint Replacement Registry has demonstrated that long-term revision rates in patients under the age of 65 have been significantly reduced by the use of computer navigation [[26](#)]. That study covered a period from 2003 to 2012 and considered over 44,000 navigated total knees of a cohort that represented 14 % of all total knees performed. The cumulative rate of revision at 9 years for younger patients was 7.8 % for conventional with a rate of 6.3 % with the use of navigation (hazard ratio: 1.38 [95 % CI = 1.13–1.67], $p = 0.001$). The most common cause of revision was implant loosening and chronic osteolysis. The conclusion was that computer navigation could be shown to improve implant survivorship in younger patients and could be shown to be cost-effective over the long term on this basis. In 2012, computer navigation has grown to include approximately 22 % of all cases in Australia.

Cons

There have been substantial detractors to the use of computer navigation and not without reasonable arguments. As noted, costs, technical complexity, and inefficiency have been major barriers for the entry of these systems into contemporary practice. Older surgeons, in general, have resisted the advent of the digital technology age, and this might include electronic health records, personal computers, video games, and, in our example, computers guiding the surgical intervention. On the other hand, this barrier has been reduced for younger surgeons who have grown up with video games and personal computers. However, Barrack et al. have fairly argued that the evidence to support the use of computer navigation in total knee replacement has been unconvincing [[54](#)]. Perhaps, a corollary is the fact that results of total knee replacement are in general satisfactory and the ability to consistently demonstrate incremental improvement is limited. The choice is not binary, allowing an equal argument for avoiding adoption.

Imageless navigation referencing suffers from inherent inaccuracy of the surgeon picking the correct proscribed anatomical reference points [[7](#), [14](#), [19](#), [42](#)]. Yau et al. compared the combined intraobserver error for image-free acquisition of reference landmarks during total knee arthroplasty finding that the maximum combined error for the coronal plane mechanical axis alignment was 1.32° [95, 96]. However, Davis et al. found that the mechanical axis of the femur in the coronal plane could vary from 5.2° valgus to 2.9° varus [[15](#)]. They point out that the clinical scenario must consider all possible errors, in this case the movement of

the pelvis with hip registration that is assumed to be fixed in space. Other errors can arise from various steps during a total knee replacement, including, for example, the placement of pins for cutting blocks, actual variation of the sawcut with subsequent bone resection errors, and errors from cementing the implants into place. These errors can be additive, and the surgeon should be constantly evaluating these effects using a navigated surface block [[14](#), [20](#)]. The results for the assessment of the transepicondylar axis or the anterior/posterior axis of Whiteside are inconsistent as compared to mechanical axis alignment [[34](#)]. This most likely reflects the difficulty in reproducibly picking the epicondylar or AP axis landmarks. The problem with the AP axis for computer navigation referencing can easily be understood by the fact that distances for landmarking are very short. Slight errors in judgment can be off by several degrees. This contrast with the mechanical axis landmarking where an error of just 1 will require a point matching mistake of at least 5 mm. Yau et al. found that errors in the transepicondylar axis could be as high as 9° [96]. Davis et al. found the transepicondylar axis error could range from 11.1° of external to 6.3° of internal rotation [[15](#)]. Restrepo et al. found that the fixed posterior condylar axis reference could result in malalignment of more than 5 in 17 % of cases as compared to other rotational axes [69]. Siston et al. have shown that femoral rotation errors could easily exceed 5° in the hands of multiple surgeons with imageless navigation referencing [[57](#)]. For femoral and tibial prosthesis rotation errors, combining computer navigation and digital registration offers the potential for improving the precision, both of the implant position and ligament balancing techniques [80, 87, 90].

There are a number of anecdotal reports of stress fracture from pin placement for navigated trackers [[3](#), [30](#), [38](#), [39](#), [43](#), [49](#), [51](#), 81]. These reports have demonstrated the larger 5 mm pins are problematic when placed bicortical in the shaft areas of the femur and tibia. Following the suggestion of Mihalko, the maximum pin thickness should be no more than 3 mm and probably should be placed unicortical in the tibia [[55](#)]. While this problem seems fairly limited, it would not appear to be isolated to extremely unlikely events.

Conclusion

We are in a transition period where an increasing amount of evidence supports the use of digital technologies for surgical image guidance. For minimally invasive applications, this guidance can be a strong asset as the exposures limit the precision of conventional instruments. As technology progresses, there will be more use of computed tomography and other imaging capabilities to improve registration and the surgeon's "view." We expect the younger generation to seek differentiation of skills with this method.

References

1. Heyse TJ, Tibesku CA. Improved femoral component rotation in TKA using patient-specific instrumentation. *Knee*. 2014;21:268–71.
[CrossRef](#) [PubMed](#)
2. Moon YW, Seo JG, Lim SJ, Yang JH. Variability in femoral component rotation reference axes measured during navigation-assisted total knee arthroplasty using gap technique. *J Arthroplasty* 2010;25:238–243.
3. Nam D, Weeks KD, Reinhardt KR, Nawabi DH, Cross MB, Mayman DJ. Accelerometer-based, portable navigation vs. imageless, large-console computer-assisted navigation in total knee arthroplasty: a comparison of radiographic results. *J Arthroplasty* 2013;28:255–61.
4. Stiehl JB, Jackson S, Szabo A. Multi-factorial analysis of time efficiency in total knee arthroplasty. *J CAS* 2009;14:1–5.
5. Bottros J, Klika AK, Lee HH, Polousky J, Barsoum WK. The use of navigation in total knee arthroplasty for patients with extra-articular deformity. *J Arthroplasty*. 2008;23(1):74–8.
[CrossRef](#) [PubMed](#)
6. Decking R, Markmann Y, Fuchs J, Puhl W, Scharf HP. Leg axis after computer- navigated total knee arthroplasty: a prospective randomized trial comparing computer-navigated and manual implantation. *J Arthroplasty*. 2005;20:282–8.
[CrossRef](#) [PubMed](#)
7. Dutton JA, Yeo SJ, Yang KY, Lo NN, Chia KU, Chong HC. Computer-assisted minimally invasive total knee arthroplasty compared with standard total knee arthroplasty. A prospective, randomized study. *J Bone Joint Surg Am*. 2008;90:2–9.
[CrossRef](#) [PubMed](#)
8. Fu Y, Wang M, Liu Y, Fu Q. Alignment outcomes in navigated total knee arthroplasty: a meta-analysis. *Knee Surg Sports Traumatol Arthrosc*. 2012;20(6):1075–82.
[CrossRef](#) [PubMed](#)
9. Hart R, Janecek M, Chaker A, Bucek P. Total knee arthroplasty implanted with and without kinematic navigation. *Int Orthop*. 2003;27:366–9.
[CrossRef](#) [PubMed](#) [PubMedCentral](#)
10. Hetaimish BM, Khan MM, Simunovic N, Al-Harbi HH, Bhandari M, Zalzal PK. Meta-analysis of navigation vs. conventional total knee arthroplasty. *J Arthroplasty*. 2012;27(6):1177–82.
[CrossRef](#) [PubMed](#)

11. Jenny JY, Clemens U, Kohler S, Kiefer H, Konermann W, Miehle RK. Consistency of implantation of a total knee arthroplasty with a non-image-based navigation system: a case-control study of 235 cases compared with 235 conventionally implanted prostheses. *J Arthroplasty*. 2005;20:832–9.
[CrossRef](#)  [PubMed](#) 
12. Jenny JY, Boeri C. Computer-assisted implantation of total knee prostheses: a case-control comparative study with classical instrumentation. *Comput Aided Surg*. 2001;6:217–20.
[CrossRef](#)  [PubMed](#) 
13. Kalairag Y, Cossey AJ, Verall GM, Ludbrook G, Spriggins AJ. Are systemic emboli reduced in computer assisted surgery. *J Bone Joint Surg*. 2005;88B:198–202.
14. Kim SJ, MacDonald M, Hernandez J, Wixson RL. Computer assisted navigation in total knee arthroplasty: improved coronal alignment. *J Arthroplasty*. 2005;20:123–31.
[CrossRef](#)  [PubMed](#) 
15. Moskal JT, Capps SG, Mann JW, Scanelli JA. Navigated versus conventional total knee arthroplasty. *J Knee Surg*. 2014;27(3):235–48.
[CrossRef](#)  [PubMed](#) 
16. Perlick L, Bathis H, Tingart M, Perlick C, Grifka J. Navigation in total-knee arthroplasty: CT-based implantation compared with conventional technique. *Acta Orthop Scand*. 2004;75:464–70.
[CrossRef](#)  [PubMed](#) 
17. Perlick L, Bathis H, Lerch K, Luring C, Tingart M, Grifka J. Navigated implantation of total knee endoprostheses in secondary knee osteoarthritis of rheumatoid arthritis patients as compared to conventional technique. *Z Rheumatol*. 2004;63:140–6.
[CrossRef](#)  [PubMed](#) 
18. Qureshi S, Lu Y, McAnany S, et al. Three-dimensional intraoperative imaging modalities in orthopedic surgery: a narrative review. *J Am Acad Orthop Surg*. 2014;22:800–9.
[CrossRef](#)  [PubMed](#) 
19. Song EK, Seon JK, Yoon TR, Park SJ, Cho SG, Yim JH. Comparative study of stability after total knee arthroplasties between navigation system and conventional techniques. *J Arthroplasty*. 2007;22(8):1107–11.
[CrossRef](#)  [PubMed](#) 
20. Stulberg SD, Loan P, Sarin V. Computer-assisted navigation in total knee replacement: results of an initial experience of thirty five patients. *J Bone Joint Surg Am*. 2002;84A:90–8.

21. Zhang GQ, Chen JY, Chai W, Liu M, Wang Y. Comparison between computer-assisted-navigation and conventional total knee arthroplasties in patients undergoing simultaneous bilateral procedures: a randomized clinical trial. *J Bone Joint Surg Am*. 2011;93(13):1190–6.
[CrossRef](#) [PubMed](#)
22. Brin YS, Nikolaou VS, Joseph L, Zukor DJ, Antoniou J. Imageless computer assisted versus conventional total knee replacement. a Bayesian meta-analysis of 23 comparative studies. *Int Orthop*. 2011;35(3):331–9.
[CrossRef](#) [PubMed](#) [PubMedCentral](#)
23. Cheng T, Zhao S, Peng X, Zhang X, Zhang X. Does computer-assisted surgery improve postoperative leg alignment and implant positioning following total knee arthroplasty? A meta-analysis of randomized controlled trials? *Knee Surg Sports Traumatol Arthrosc*. 2012;20:1307–22.
[CrossRef](#) [PubMed](#)
24. Khakha RS, Chowdhry M, Norris M, Kheiran A, Chauhan SK. Low incidence of complications in computer assisted total knee arthroplasty-A retrospective review of 1596 cases. *Knee*. 2015.
doi:10.1016/j.knee.2015.02.009. [Epub ahead of print].
25. Kuzyk PR, Higgins GA, Tunggal JA, Sellan ME, Waddell JP, Schemitsch EH. Computer navigation vs. extramedullary guide for sagittal alignment of tibial components: radiographic study and meta-analysis. *J Arthroplasty*. 2012;27(4):630–7.
[CrossRef](#) [PubMed](#)
26. De Steiger RN, Liu Y-L, Graves SE. Computer navigation for total knee arthroplasty reduces revision rate for patients less than sixty-five years of age. *J Bone Joint Surg*. 2015;97:635–42.
[CrossRef](#) [PubMed](#)
27. Millar NL, Deakin AH, Millar LL, Kinnimonth AW, Picard F. Blood loss following total knee replacement in the morbidly obese: effects of computer navigation. *Knee*. 2011;18(2):108–12.
[CrossRef](#) [PubMed](#)
28. Schnurr C, Csécei G, Eysel P, König DP. The effect of computer navigation on blood loss and transfusion rate in TKA. *Orthopedics*. 2010;33(7):474.
[PubMed](#)
29. Young KL, Dunbar MJ, Richardson G, Astephen Wilson JL. Modern abbreviated computer navigation of the femur reduces blood loss in total knee arthroplasty. *J Arthroplasty*. 2015.
doi:10.1016/j.arth.2015.04.020. [Epub ahead of print].

30. Kalairag Y, Simpson P, Cossey AJ, Verrall GM, Spriggins AJ. Blood loss after total knee arthroplasty, effects of computer assisted surgery. *J Bone Joint Surg.* 2005;87B:1480–2.

[CrossRef](#) 

31. McConnell J, Dillon J, Kinninmonth A, Sarungi M, Picard F. Blood loss following total knee replacement is reduced when using computer-assisted versus standard methods. *Acta Orthop Belg.* 2012;78(1):75–9.

[PubMed](#) 

32. Ishida K, Matsumoto T, Tsumura N, Kubo S, Kitagawa A, Chin T, Iguchi T, Kurosaka M, Kuroda R. Mid-term outcomes of computer-assisted total knee arthroplasty. *Knee Surg Sports Traumatol Arthrosc.* 2011;19(7):1107–12.

[CrossRef](#)  [PubMed](#) 

33. Lützner J, Günther KP, Kirschner S. Functional outcome after computer-assisted versus conventional total knee arthroplasty: a randomized controlled study. *Knee Surg Sports Traumatol Arthrosc.* 2010;18(10):1339–44.

[CrossRef](#)  [PubMed](#) 

34. Gøthesen O, Espehaug B, Havelin LI, Petursson G, Hallan G, Strøm E, Dyrhovden G, Furnes O. Functional outcome and alignment in computer-assisted and conventionally operated total knee replacements: a multicentre parallel-group randomised controlled trial. *Bone Joint J.* 2014;96-B(5):609–18.

[CrossRef](#)  [PubMed](#) 

35. Hoffart HE, Langenstein E, Vasak N. A prospective study comparing the functional outcome of computer-assisted and conventional total knee replacement. *J Bone Joint Surg Br.* 2012;94(2):194–9.

[CrossRef](#)  [PubMed](#) 

36. Heyse TJ, Chong LR, Davis J, et al. MRI analysis for rotation of total knee components. *Knee.* 2012;19:571–5.

[CrossRef](#)  [PubMed](#) 

37. Victor J, Van Doninck D, Labey L, et al. How precise can bony landmarks be determined on a CT scan of the knee? *Knee.* 2009;16:358–65.

[CrossRef](#)  [PubMed](#) 

38. Roper GE, Bloemke AD, Roberts CC, et al. Analysis of tibial component rotation following total knee arthroplasty using 3D high definition computed tomography. *J Arthroplasty.* 2013;28(Supp 1):106–11.

[CrossRef](#)  [PubMed](#) 

39. Kuriyama S, Hyakuna K, Inoue S, Tamaki Y, Ito H, Matsuda S. Tibial rotational alignment was significantly improved by use of a CT-navigated control device in total knee arthroplasty. *J Arthroplasty*. 2014;29(12):2352–6.
[CrossRef](#) [PubMed](#)
40. Joseph J, Simpson PM, Whitehouse SL, English HW, Donnelly WJ. The use of navigation to achieve soft tissue balance in total knee arthroplasty – a randomised clinical study. *Knee*. 2013;20(6):401–6.
[CrossRef](#) [PubMed](#)
41. Pang HN, Yeo SJ, Chong HC, Chin PL, Ong J, Lo NN. Computer-assisted gap balancing technique improves outcome in total knee arthroplasty, compared with conventional measured resection technique. *Knee Surg Sports Traumatol Arthrosc*. 2011;19(9):1496–503.
[CrossRef](#) [PubMed](#)
42. Stiehl JB, Heck DA. How precise is computer assisted gap assessment in navigated total knee replacement. *Clin Orthop Relat Res*. 2015;473:115–8.
[CrossRef](#) [PubMed](#) [PubMedCentral](#)
43. Walde TA, Bussert J, Sehmisch S, Balcarek P, Stürmer KM, Walde HJ, Frosch KH. Optimized functional femoral rotation in navigated total knee arthroplasty considering ligament tension. *Knee*. 2010;17(6):381–6.
[CrossRef](#) [PubMed](#)
44. Hino K, Ishimaru M, Iseki Y, Watanabe S, Onishi Y, Miura H. Mid-flexion laxity is greater after posterior-stabilised total knee replacement than with cruciate-retaining procedures: a computer navigation study. *Bone Joint J*. 2013;95-B(4):493–7.
[CrossRef](#) [PubMed](#)
45. Colle F, Bignozzi S, Lopomo N, Zaffagnini S, Sun L, Marcacci M. Knee functional flexion axis in osteoarthritic patients: comparison in vivo with transepicondylar axis using a navigation system. *KRSST* 2012;20:552058.
46. Matziolis G, Pfiel S, Wassilew G, Boenicke H, Perka C. Kinematic analysis of the flexion axis for correct femoral component placement. *Knee Surg Sports Traumatol Arthrosc*. 2011;19(9):1504–9.
[CrossRef](#) [PubMed](#)
47. Siston RA, Cromie MJ, Gold GE, Goodman SB, Delp SL, Maloney WJ, Giori NJ. Averaging different alignment axes improves femoral rotational alignment in computer-navigated total knee arthroplasty. *J Bone Joint Surg Am*. 2008;90:2098–104.

48. Young KL, Dunbar MJ, Richardson G, Astephen Wilson JL. Intraoperative passive knee kinematics during total knee arthroplasty surgery. *J Orthop Res*. 2015. doi:10.1002/jor.22945. [Epub ahead of print].

49. Catani F, Digennaro V, Ensini A, Leardini A, Giannini S. Navigation-assisted total knee arthroplasty in knees with osteoarthritis due to extra-articular deformity. *Knee Surg Sports Traumatol Arthrosc*. 2012;20(3):546–51.

50. Kim KK, Heo YM, Won YY, Lee WS. Navigation-assisted total knee arthroplasty for the knee retaining femoral intramedullary nail, and distal femoral plate and screws. *Clin Orthop Surg*. 2011;3(1):77–80.

51. Kuo CC, Bosque J, Meehan JP, Jamali AA. Computer-assisted navigation of total knee arthroplasty for osteoarthritis in a patient with severe posttraumatic femoral deformity. *J Arthroplasty*. 2011;26(6):976.

52. Mullaji A, Lingaraju AP, Shetty GM. Computer-assisted total knee replacement in patients with arthritis and a recurvatum deformity. *J Bone Joint Surg Br*. 2012;94(5):642–7.

53. Mullaji AB, Shetty GM, Kanna R, Vadapalli RC. The influence of preoperative deformity on valgus correction angle: an analysis of 503 total knee arthroplasties. *J Arthroplasty*. 2013;28(1):20–7.

54. Burnett RSJ, Barrack RL. Computer-assisted total knee arthroplasty is currently of no proven clinical benefit: a systematic review. *Clin Orthop Relat Res*. 2013;471:264–76.

55. Haaker RG, Stockheim M, Kamp M, Proff G, Breitenfelder J, Ottersbach A. Computer-assisted navigation increases precision of component placement in total knee arthroplasty. *Clin Orthop Rel Res*. 2005;433:152–9.

56. Sparmann M, Wolke B, Czupalla H, Banzer D, Zink A. Positioning of total knee arthroplasty with and without navigation support. A prospective, randomised study. *J Bone Joint Surg Br*. 2003;85(6):830–5.

57. Victor J, Hoste D. Image-based computer-assisted total knee arthroplasty leads to lower variability in coronal alignment. *Clin Orthop Relat Res*. 2004;428:131–9.

58. Bathis H, Perlick L, Tingart M, Luring C, Zurakowski D, Grifka J. Alignment in total knee arthroplasty. A comparison of computer-assisted surgery with the conventional technique. *J Bone and Joint Surg.* 2004;86B:682–87.
59. Anderson KC, Buehler KC, Markel DC. Computer assisted navigation in total knee arthroplasty. *J Arthroplasty.* 2005;20:132–8.